



# INTERNATIONAL JOURNAL OF PHARMACEUTICAL RESEARCH AND BIO-SCIENCE

## ATYPICAL PRESENTATION OF A DERMOID CYST

PROF. K. MOHAN RAJ<sup>1</sup>, DR. FATHIMA JEHAN<sup>2</sup>, DR. BHARGAVI<sup>3</sup>

1. PROFESSOR AND HEAD OF THE DEPARTMENT OF OPHTHALMOLOGY, SREE BALAJI MEDICAL COLLEGE & HOSPITAL, CHROMEPET, CHENNAI-600044
2. POST GRADUATE OF OPHTHALMOLOGY, SREE BALAJI MEDICAL COLLEGE & HOSPITAL, CHROMEPET, CHENNAI-600044
3. POST GRADUATE OF OPHTHALMOLOGY, SREE BALAJI MEDICAL COLLEGE & HOSPITAL, CHROMEPET, CHENNAI-600044

Accepted Date: 06/02/2016; Published Date: 27/02/2016

**Abstract:** Dermoid cysts are smooth, tense, rounded or hourglass shaped tumours. Of all dermoids occurring in head and neck, 50% are in the orbital region and of those 60% are situated in outer third of upper lid and brow. In our case, 29 year old male presented with a huge swelling on the outer half of right eyelid. Skin was freely movable over the swelling and it was not adherent to the underlying bone. This case indicated how a common swelling presented in a different manner and can pose a problem in clinical diagnosis.

**Keywords:** Dermoid cyst, trans illumination, sebaceous hyperplasia, Casoni's test



PAPER-QR CODE

Corresponding Author: PROF. K. MOHAN RAJ

Access Online On:

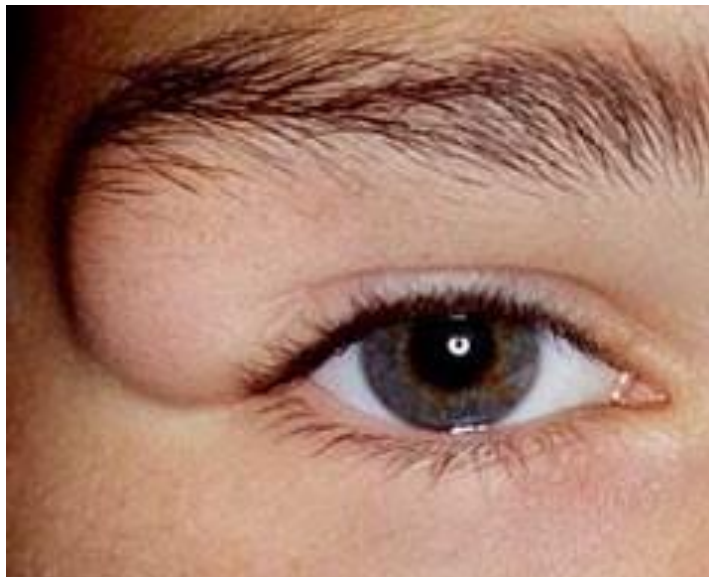
[www.ijprbs.com](http://www.ijprbs.com)

How to Cite This Article:

K. Mohan Raj, IJPRBS, 2016; Volume 5(1): 92-95

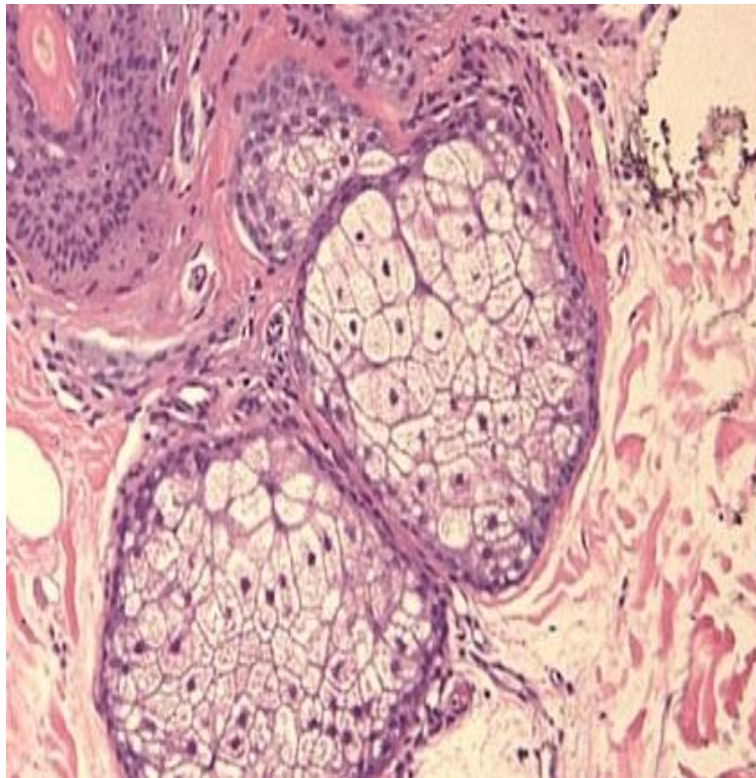
## INTRODUCTION

A 29 year old male presented to Department of Ophthalmology, Sree Balaji Medical College and Hospital with a complaint of huge swelling on the outer half of right eyelid . The swelling was present since childhood and has increased steadily to the present size . Skin was freely movable over the swelling . The swelling was also not attached to the deeper structures . The consistency of the swelling was soft and not tender . It was not reducible . There was no impulse on coughing and not pulsatile . Transillumination was positive . Anterior and posterior segments of both eyes were normal.



**Fig1: dermoid cyst**

Hemogram was within normal limits. Motion examination was normal. Mantoux and Casoni's tests were negative. Xray of right orbit showed only soft tissue shadow without bony erosion. Swelling was excised in toto . The cyst was found attached to the undersurface of supraorbital margin . The cyst was filled with clear oily fluid , which on histopathological examination showed cholesterol crystals. The wall of the cyst showed squamous epithelial lining , hair follicles and hyperplasia of sebaceous glands .



**Fig2: Histopathological image showing sebaceous gland hyperplasia.**

Initially the diagnosis of lymphangioma was thought of due to the boggy swelling and translucency . It was differentiated from sebaceous cyst since the skin was not attached to the swelling . Cephalocele was differentiated due to the absence of reducibility and lack of impulse on coughing and cerebral symptoms. Hydatid cyst was ruled out due to negative Casoni's test . The boggy swelling with positive transillumination eluded the diagnosis of dermoid cyst . The diagnosis which was suggested during operation was confirmed after histopathological report . Since the cyst consisted of almost transparent fluid , it has not eroded the bone . This case is been reported for its atypical presentation.

#### REFERENCES:

1. Jones IS, Jakobiec FA, Nollan BT. Patent examination and introduction to orbital disease. In: Duane TD, ed. Clinical ophthalmology 11: the orbit. Hagerstown: Harper and Row 1976; 1-30).
2. Pfeiffer RL, Nicholl RJ. Dermoid and epidermoid tumours of the orbit. Arch Ophthalmol 1948; 40: 639.
3. Moss HM. Expanding lesions of the orbit. A clinical study of 23 consecutive cases. Am J Ophthalmol 1962; 54: 761.

4. Grovc AS Jr. Orbital disorders: diagnosis and managemcnt. In: McCord CD Jr. ed. Oculoplastic.surgery. Ncw York: Raven Press, 1981; 274-7.
5. Pollard ZF, Calhoun MD. Dccp orbital dermoid with draining sinus. Ain J Ophthalmol 1975; 79: 31t)-13.
6. Cullen JF. Orbital diploic dermoids. Br J Ophthalmol 1974; 58: 1(05-6.
7. Grovc AS Jr. Giant dermoid cysts of the orbit. Ophthalmology 1979;86: 1513-2).
8. Kcnnedy RE. Marsupilization of inoperable orbital dermoids. Trans Ain Ophthalmol Soc 1970); 68: 146-64.